

# Titan Tests

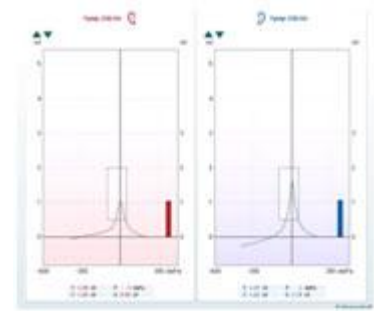


**Interacoustics<sup>®</sup>**

leading diagnostic solutions

### Tympanometry (226 Hz, 678 Hz, 800 Hz, 1000 Hz)

**Short description:** Presenting a tone into a cavity like the human ear will produce different sound pressure levels depending on the volume of the cavity and the ease of sound flow through the tympanic membrane and ossicular chain. A Tympanogram is a graphical representation of the compliance of the human ear as a function of the air pressure in the outer ear canal. It is measured by sealing the ear with a probe and presenting a tone (226 Hz, 678 Hz, 800 Hz, 1000 Hz) while the air pressure in the outer ear canal is changed.

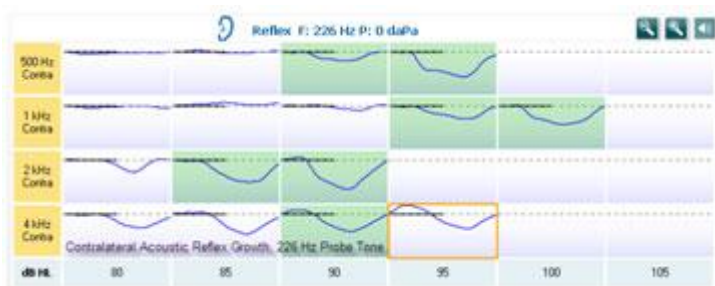


**Purpose:** The purpose of tympanometry is to investigate the volume of the ear canal and stiffness of the middle ear. A Tympanogram helps to distinguish between normal middle ear function and different kinds of middle ear abnormalities. When measuring the admittance in babies, it is strongly recommended that a higher frequency stimulus (e.g. 1000 Hz) be used.

### Acoustic Reflex

**Short description:** The acoustic reflex refers to the reflexive contraction of the middle ear muscles evoked by intense sound stimulation. It causes changes in the acoustic immittance of the middle ear which can be measured in both the ipsi- and contralateral ear. The acoustic reflex is measured by sealing the ear with a probe and presenting a tone (226 Hz, 678 Hz, 800 Hz, 1000 Hz) as well as a sound as a function of time.

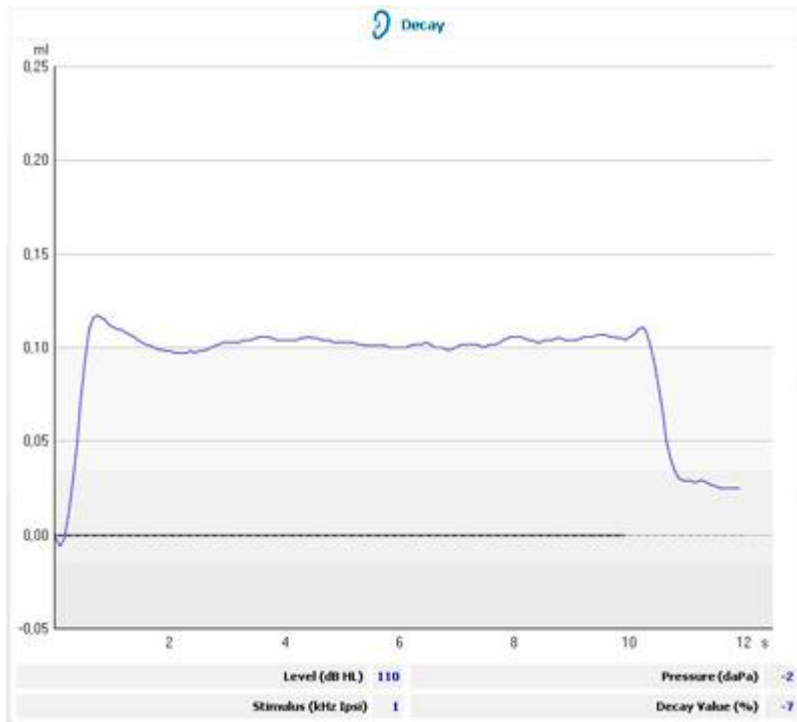
**Purpose:** The purpose of reflex measurements is to identify the presence of thresholds for both ipsi- and contralateral stimulation. Acoustic reflexes are valuable in helping to distinguish between middle ear and inner ear (and some neurological) abnormalities.



### Reflex Decay

**Short description:** Reflex decay is an acoustic reflex measurement that shows the amplitude of stapedial muscle contraction over time during the presentation of a sustained stimulus. The acoustic reflex response is recorded for 10 up to 30 seconds at a level 10 dB above the acoustic reflex threshold.

**Purpose:** The presence of an abnormally rapid reflex decay is associated with retrocochlear disorders.



#### Acoustic Reflex Latency

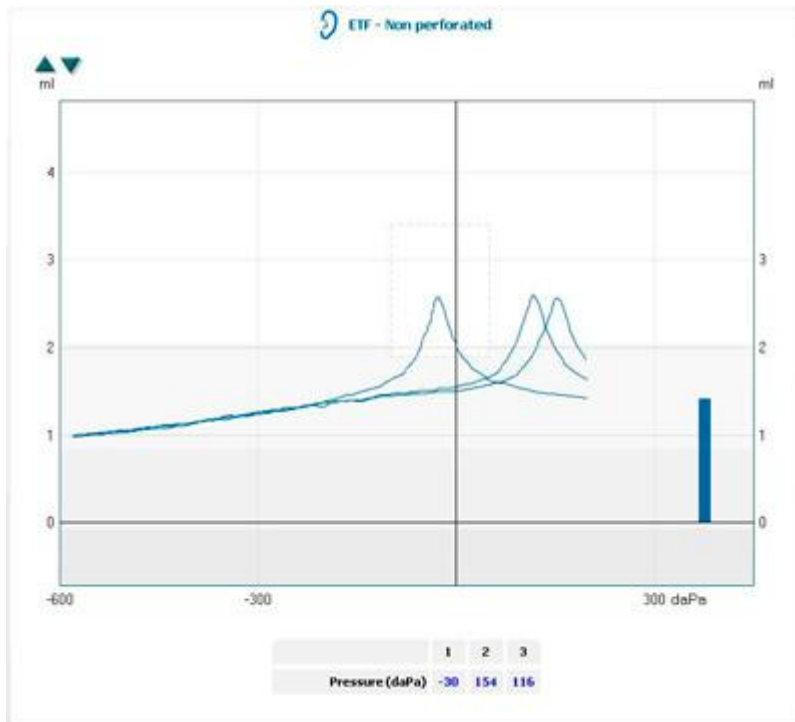
**Short description:** The Latency test shows the first part of an acoustic reflex in detail.

**Purpose:** Investigation of the details of the onset of an acoustical reflex as function of the stimulus type and intensity level.

#### Eustachian Tube Function, Non Perforated Eardrum – Williams Test

**Short description:** The Williams test consists of three separately measured tympanograms. Between the different measurements the patient is instructed to decrease middle ear pressure by swallowing and increase middle ear pressure by performing the valsalva maneuver.

**Purpose:** The purpose of the Williams test is to investigate if the patient (with non-perforated eardrum) is able to operate his Eustachian tube.



#### Eustachian Tube Function, Perforated Eardrum – Toynbee Test

**Short description:** The Toynbee test measures the middle ear pressure as a function of time. After the ear is sealed by the probe, the air pressure in the middle ear is lowered or raised (through the perforation). Depending on the starting pressure, the patient is then asked to either swallow several times or to perform the valsalva maneuver.

**Purpose:** The purpose of the Toynbee test is to investigate if the patient (with a perforated eardrum) is able to operate his Eustachian tube.

#### Eustachian Tube Function, Patulous Eustachian tube

**Short description:** The compliance is monitored in detail as a function of time (without applying any stimulus movements of the ear drum will result in a change in compliance, which is then captured in the recording).

**Purpose:** A possible patulous Eustachian tube can be identified when the rhythm of breathing is recognized in the recording. Other applications of this test are for the monitoring of acoustic reflexes evoked through a cochlear implant, as well as for recognizing the heart beat in the compliance measurement which, in rare occasions, can indicate the presence of a glomus tumor.